

## Can Arabic gum improve the fertility impairment and ameliorate the oxidative stress induced by aluminum chloride in male rats?

Sahar M. Abo El Wafa<sup>1</sup>, Mohamed A. Salem<sup>2</sup>

<sup>1</sup>Department of Forensic Medicine and Clinical Toxicology, Faculty of Medicine, Benha University, Benha, Egypt

<sup>2</sup> Pharmaceutical Chemistry Department (Organic Chemistry branch), Faculty of Pharmacy, October 6 University, Egypt

---

### Abstract

**Background:** Aluminum (Al) considered the third most ground element present everywhere which is nonessential and toxic metal to humans and accumulates in target organs causing serious effects on different systems including male reproductive system. Arabic gum (AG) is a dried exudate obtained from the stems and branches of Acacia Senegal tree and has antioxidant compounds that have ability to scavenging the free radicals, activation of antioxidant enzymes and inhibition of oxidases. **Aim:** This study evaluates the modulating effect of Arabic gum (AG) on fertility impairment and oxidative stress-induced from exposure to aluminum chloride (AlCl<sub>3</sub>) on adult male albino rats. **Materials and methods:** Thirty two male albino rats were divided randomly into four equal groups. Group I: served as control received only oral distilled water. Group II: rats were given AG by oral gavage (7.5 g/kg/day). Group III: received AlCl<sub>3</sub> (100 mg/kg) orally. Group IV: received oral AlCl<sub>3</sub> (100 mg/kg) and AG (7.5 g/kg) simultaneously for 60 consecutive days. Blood samples were taken to measure antioxidant state and testosterone level also semen samples were collected for semen analysis and histopathological study was also done.

**Results:** Simultaneous administration of AG with AlCl<sub>3</sub> produced highly significant increase in plasma level of GSH, SOD and CAT with highly significant decrease in plasma level of MDA when compared to the AlCl<sub>3</sub> group. Fertility study regarding treatment of AlCl<sub>3</sub> intoxicated rats with AG showed improvement in testosterone hormone level and semen analysis as there were highly significant increase in testosterone hormone level, sperm count, sperm motility, sperm viability with highly significant decrease in total sperm abnormality compared to AlCl<sub>3</sub> group. Also, histopathological changes occurred in AlCl<sub>3</sub> group were improved with concomitant administration of AG with AlCl<sub>3</sub>. **Conclusion:** AG is an effective protective agent against AlCl<sub>3</sub>-induced fertility impairment and oxidative stress due to its ability to decrease the oxidative stress and preserve the activity of antioxidant enzymes.

**Keywords:** Arabic gum, aluminum chloride, oxidative stress, fertility, testis.

---

Date of Submission: 07-08-2020

Date of Acceptance: 21-08-2020

---

### I. Introduction

Aluminum (Al) considered the third most ground element which is nonessential and toxic metal in humans<sup>1</sup>. With development in industries and increased pollution, aluminum gets more into our bodies through the air, water, foods and unfortunately drugs<sup>2</sup>. It can be found in food stuff especially yellow cheese, salt, herbs, tea leaves and food additives<sup>3</sup>. In addition, Aluminum salts such as aluminum chloride (AlCl<sub>3</sub>) used in purification and treatment of drinking water so it is easy enters our bodies through GIT<sup>4</sup>. Also aluminum used in homes, hospitals, schools, cosmetics as in deodorants<sup>5</sup>.

Animal studies on aluminum toxicity revealed that aluminum accumulates in target organs and causes serious effects on various systems of the body including the male reproductive system<sup>6</sup>.

Aluminum causes its abnormalities through formation of (ROS) and decreasing of antioxidant system<sup>7</sup>.

Also, aluminum causes its reproductive toxicity by different mechanisms as increasing the oxidative stress, affecting spermatogenesis and damaging of the blood-testes barrier<sup>6</sup>.

Necrosis of spermatocytes due to aluminum accumulation and notable impairment in fertility also seen in both male rats and mice<sup>8,9</sup>.

Intake of antioxidants created in the body or taken from food may improve the damage caused by oxidative stress by inhibiting of the oxidative chain reactions<sup>10</sup>.

Arabic gum (AG) is a dried exudate obtained from the stems and branches of Acacia seyal and Acacia Senegal tree and rich in non-viscous soluble fibers<sup>11</sup>. It consists mainly of polysaccharides of high molecular weight, containing neutral and acids sugars<sup>12</sup>, and minerals<sup>13</sup>. Gum Arabic has wide industrial uses in pharmacology

and foods <sup>14</sup>. The antioxidant characters of Gum Arabic were mentioned in many animal model systems by <sup>15</sup>. Gum Arabic as antioxidant contains flavone, catechin, polyphenols, tannins, chalcones, alkaloids and flavonoids <sup>16</sup>. These compounds have ability to scavenging the free radicals, activation of antioxidant enzymes and inhibition of oxidases <sup>17</sup>.

Hence research on the effect of Arabic gum against aluminum chloride induced oxidative stress and fertility impairment has not so far been studied, therefore the present work aimed to evaluate this possible protective effect.

## **II. Materials and methods**

### **Drugs:**

1. Aluminum Chloride anhydrous ( $\text{AlCl}_3$ ) was purchased from El-Gomhouria Co. For Trading Chemicals And Medical Appliances (Egypt).
2. Arabic gum (AG) was purchased in powder form with high purity from Sigma-Aldrich (St Louis, MO, USA).
3. All other chemicals were of the highest grade commercially available.

### **Animals:**

Thirty two male albino rats, 5 months old, 200-250g used in this study obtained from Experimental Animal Breeding Farm, (Helwan-Cairo) for 60 consecutive days. They were caged 8 per cage in well-ventilated place at room temperature at the department of pharmacology, Benha Faculty of Medicine. They allowed for 2 weeks of acclimatization with free water and standard food (pellets specific for rat feeding obtained from the animal breeding farm) on a schedule of 12 hours of light and 12 hours of dark. The time of dose administration was fixed for all animals at 12 P.M. During the whole period of experiment, animals were treated humanely according to the protocol of handling of experimental animals of Benha Faculty of Medicine and every effort made to decrease the number of animals used and their suffering.

The animals were divided randomly into four equal Groups as following:

Group I: served as control receive only distilled water.

Group II: rats were given AG (7.5 g/kg/day) <sup>18</sup>.

Group III: received  $\text{AlCl}_3$  (100 mg/kg) <sup>19</sup>.

Group IV: received  $\text{AlCl}_3$  (100 mg/kg) and AG (7.5 g/kg) simultaneously.

The animals of all groups were given doses orally by nasogastric tube and the experiment remained for 60 consecutive days. At the end of the study, blood samples were collected in sterile tubes from all rats of different groups to measure antioxidant state and testosterone level evaluation. Then, animals were sacrificed by decapitation and dissected to obtain epididymis for semen analysis and histopathological study.

### **Antioxidant state estimation**

Plasma Glutathione (GSH) and Superoxide dismutase (SOD) concentrations were estimated spectrophotometrically at 405 nm and 560 nm according to methods of Beutler et al. <sup>20</sup> and Nishikimi et al. <sup>21</sup>, respectively. Malondialdehyde (MDA) was determined spectrophotometrically in plasma at 534 nm according to Onkawa et al. <sup>22</sup>. Catalase (CAT) concentration was determined according to Sinha <sup>23</sup>.

### **Testosterone hormone level and semen analysis assessment**

Serum testosterone level was evaluated by radioimmunoassay according to Wilson and Foster <sup>24</sup>. Epididymis tail content of each rat collected by squeezed slowly in sterile glass containing one ml of 2.9% sodium citrate solution for semen analysis according to Bearden and Flaquary <sup>25</sup>.

### **Histopathological study**

At the end of the study animals were sacrificed by decapitation and dissected then testes were removed and fixed in 10% buffered formalin then processed and stained with haematoxylin and eosin (H&E) according to Bancroft et al. <sup>26</sup>, after that subjected to pathological examination by the light microscope.

### **Statistical analysis**

Results were collected, tabulated and expressed as mean  $\pm$  standard deviation. Statistical comparisons were performed using one-way analysis of variance (ANOVA) to compare mean values between treatment groups and control using SPSS version 16. P value  $\leq 0.05$  was considered statistically significant.

### III. Results

**Table (1): Statistical comparison between all studied groups regarding Malondialdehyde (MDA), plasma Glutathione (GSH), Superoxide dismutase (SOD) and Catalase (CAT) by ANOVA test**

	Group (I) Control group	Group (II) Arabic Gum (AG) group	Group (III) Aluminum (AlCl <sub>3</sub> ) group	Group (IV) AlCl <sub>3</sub> + AG group	F test	P value
MDA level ( $\mu\text{mol/L}$ )	10.42 $\pm$ 1.02	8.41 $\pm$ 0.99 \$**	28.42 $\pm$ 1.23 \$^***	13.60 $\pm$ 0.98 \$^{\wedge}\epsilon^{**}	582	0.000**
GSH level ( $\text{mmol/L}$ )	72.26 $\pm$ 1.80	79.72 $\pm$ 0.99 \$**	52.31 $\pm$ 1.56 \$^***	63.89 $\pm$ 1.61 \$^{\wedge}\epsilon^{**}	477.76	0.000**
SOD level (u/ml)	296.90 $\pm$ 7.26	309.70 $\pm$ 1.15 \$**	198.68 $\pm$ 1.41 \$^***	273.58 $\pm$ 3.93 \$^{\wedge}\epsilon^{**}	110.3	0.000**
CAT level (u/ml)	20.38 $\pm$ 1.31	24.53 $\pm$ 1.25 \$**	12.48 $\pm$ 1.18 \$^***	17.42 $\pm$ 1.26 \$^{\wedge}\epsilon^{**}	131.55	0.000**

All values are expressed as mean $\pm$ SD

Number of rats in each group = 8

The mean difference is significant at the 0.05 level.

highly significant(\*\*)

\$: indicate significant change as compared with a group (I)

^: indicate significant change as compared with a group (II)

€: indicate significant change as compared with a group (III)

F test= ANOVA test

The modulating effect of Arabic gum (AG) on the oxidative stress-induced by aluminum chloride (AlCl<sub>3</sub>) exposure was obvious which is showed in **table (1)**. AlCl<sub>3</sub>intoxicated group resulted in highly significant decrease ( $p<0.05$ ) in plasma level of GSH, SOD and CAT and highly significant increase ( $p<0.05$ ) in plasma level of MDA when compared to the control group. Simultaneous administration of AG with AlCl<sub>3</sub> produced highly significant increase in plasma level of GSH, SOD and CAT with highly significant ( $p<0.05$ ) decrease in plasma level of MDA when compared to the AlCl<sub>3</sub> group. It is also notable that AG group showed highly significant ( $p<0.05$ ) increase in plasma level of GSH, SOD and CAT with highly significant ( $p<0.05$ ) decrease in plasma level of MDA when compared to the control group.

**Table (2): Statistical comparison between all studied groups regarding testosterone hormone level and semen analysis assessment by ANOVA test**

	Group (I) Control group	Group (II) Arabic Gum (AG) group	Group (III) Aluminum (AlCl <sub>3</sub> ) group	Group (IV) AlCl <sub>3</sub> + AG group	F test	P value
Testosterone hormone level ( $\text{ng/ml}$ )	2.54 $\pm$ 0.68	3.47 $\pm$ 0.85 \$**	1.38 $\pm$ 0.72 \$^***	2.39 $\pm$ 0.68 \$^{\wedge}\epsilon^{**}	10.84	0.000**
Sperm count ( $\times 10^6/\text{ml}$ )	2.33 $\pm$ 0.49	2.83 $\pm$ 0.23 \$**	1.61 $\pm$ 0.48 \$^***	2.47 $\pm$ 0.53 \$^{\wedge}\epsilon^{**}	8.08	0.000**
Sperm motility (%)	85.64 $\pm$ 3.71	91.52 $\pm$ 2.33 \$**	72.34 $\pm$ 1.36 \$^***	83.17 $\pm$ 0.81 \$^{\wedge}\epsilon^{**}	94.88	0.000**
Sperm viability (%)	90.36 $\pm$ 1.17	94.22 $\pm$ 0.90 \$**	79 $\pm$ 0.7 \$^***	84.16 $\pm$ 0.73 \$^{\wedge}\epsilon^{**}	451.21	0.000**
Total abnormality (%)	10.08 $\pm$ 0.65	7.13 $\pm$ 0.66 \$**	33.05 $\pm$ 0.66 \$^***	12.09 $\pm$ 0.63 \$^{\wedge}\epsilon^{**}	2.63	0.000**

All values are expressed as mean $\pm$ SD

Number of rats in each group = 8

The mean difference is significant at the 0.05 level.

highly significant(\*\*)

\$: indicate significant change as compared with a group (I)

^: indicate significant change as compared with a group (II)

€: indicate significant change as compared with a group (III)

F test= ANOVA test

Regarding testosterone hormone level and semen analysis **table (2)** showed that AlCl<sub>3</sub>intoxication resulted in highly significant ( $p<0.05$ ) decrease in testosterone hormone level, sperm count, sperm motility, sperm viability with highly significant increase ( $p<0.05$ ) in total sperm abnormality when compared with the control group. On the other hand, when AG was simultaneously administrated with AlCl<sub>3</sub> there was highly significant increase ( $p<0.05$ ) in testosterone hormone level, sperm count, sperm motility, sperm viability with

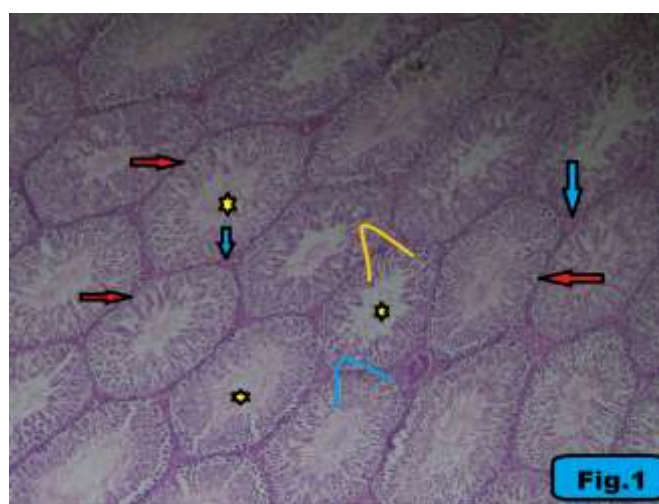highly significant ( $p < 0.05$ ) decrease in total sperm abnormality when compared with  $AlCl_3$  group. Also it is notable that AG group showed highly significant ( $p < 0.05$ ) increase in testosterone hormone level, sperm count, sperm motility, sperm viability with highly significant ( $p < 0.05$ ) decrease in total sperm abnormality when compared with the control group.

Concerning the histopathological study, the testis of control group showed normal architecture with crowded, closely packed seminiferous tubules lined by stratified spermatogenic epithelium with spermatozoa seen within the lumen and the interstitial spaces show Leydig cells (**Fig.1**).

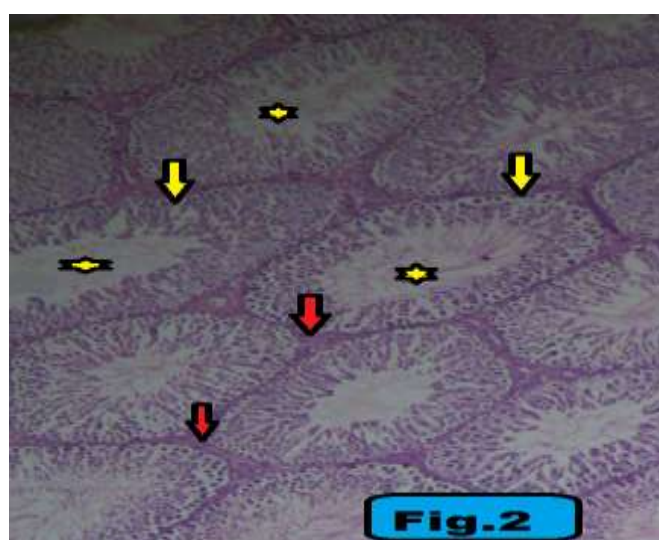
The testis of AG group (group II) showed normal architecture with crowded, closely packed seminiferous tubules with spermatozoa seen within the lumen and the interstitial spaces show Leydig cells (**Fig.2**).

The testis of  $AlCl_3$  group (group III) showed degenerated spermatogenic epithelium and loss of the releasing spermatozoa. Also pyknotic nuclei of the spermatogenic cell were seen; the interstitial spaces show eosinophilic fluid (edema) with infiltration of mononuclear cells and vacuolation (**Fig.3**).

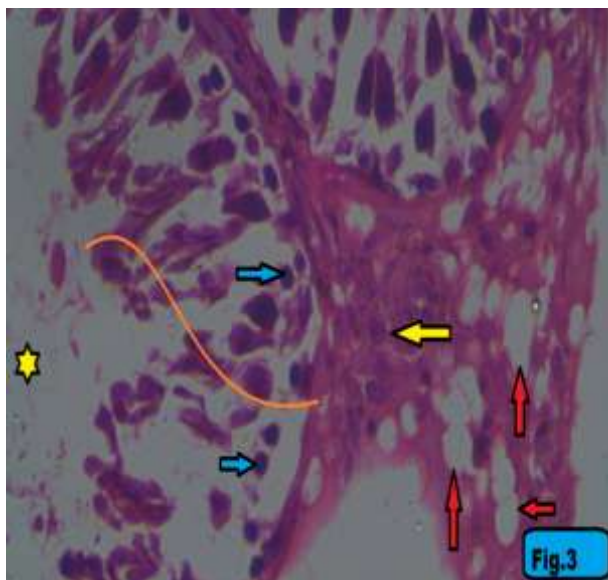
The testis of  $AlCl_3$  + AG group (group IV) showed normal shaped seminiferous tubules lined by stratified spermatogenic epithelium with normal releasing spermatozoa within the lumen and the interstitial space shows accumulation of eosinophilic fluid (edema) (**Fig.4**).



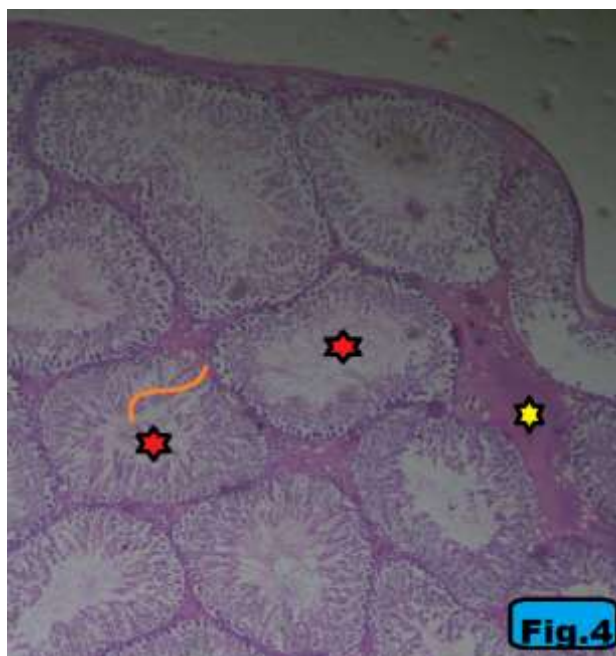
**Fig.(1):** Photomicrograph section in the testis of control group shows normal architecture with crowded, closely packed seminiferous tubules (red arrow) lined by stratified spermatogenic epithelium (orange and blue lines) with spermatozoa (yellow star) seen within the lumen. The interstitial spaces show Leydig cells (blue arrow) (**H & E X40**).



**Fig.(2):** Photomicrograph section in the testis of Arabic Gum group (group II) shows normal architecture with crowded, closely packed seminiferous tubules (yellow arrow) with spermatozoa (yellow star) seen within the lumen. The interstitial spaces show Leydig cells (red arrow) (**H & E X40**).



**Fig. (3):** Photomicrograph section in the testis of aluminium chloride group (group III) shows degenerated spermatogenic epithelium (orange line) and loss of the releasing spermatozoa (yellow star). Pyknotic nuclei of the spermatogenic cell (blue arrow). The interstitial spaces show eosinophilic fluid (edema) with infiltration of mononuclear cells (yellow arrow) and vacuolation (red arrow) (H & E X400).



**Fig. (4):** Photomicrograph section in the testis of aluminium chloride+ Arabic Gum group (group IV) shows normal shaped seminiferous tubules lined by stratified spermatogenic epithelium with normal releasing spermatozoa (red star) within the lumen. The interstitial space shows accumulation of eosinophilic vacuolated fluid (yellow star) (H & E X40).

#### IV. Discussion

The widespread of aluminum in the surrounding environment makes the exposure to this pollutant inevitable<sup>27</sup>. These days, excess exposure to aluminum by different way increases the risk of its toxicity which results in hazardous effect to different body systems<sup>28</sup>.

Gum Arabic as antioxidant contains flavone, catechin, polyphenols, tannins, alkaloids and flavonoids<sup>16</sup>. These compounds have ability to scavenging the free radicals, activation of antioxidant enzymes and inhibition of oxidases<sup>17</sup>.

The current study aimed to evaluate the protective effect of Arabic gum (AG) against the oxidative stress and fertility impairment resulted from exposure to aluminum chloride ( $AlCl_3$ ) intoxication.

Concerning the effect of  $AlCl_3$  on oxidative stress, the current work revealed that  $AlCl_3$  intoxication resulted in highly significant decrease in plasma level of GSH, SOD and CAT with highly significant increase in plasma level of MDA. This is similar to the results reported by **Abdelazem**<sup>29</sup> who revealed that there was decrease in GSH, SOD and CAT activity with increase in MDA activity in aluminum intoxicated rats. Also **Hammoud and Shalaby**<sup>30</sup> founded in their study on rats that  $AlCl_3$  resulted in decrease in plasma level of GSH and SOD and increase in plasma level of MDA. Also this result was in agreement with the study done by **Cheraghiet al.**<sup>31</sup> who reported that aluminum resulted in oxidative stress in rat's testes and cause changes in the antioxidant system. This may be resulted from ability of aluminum to produce oxidative stress, cross the blood-testes barrier and activation of lipid peroxidation system<sup>9</sup>.

Also in the current work simultaneous administration of AG with  $AlCl_3$  produced significant increase in plasma level of GSH, SOD and CAT with significant decrease in plasma level of MDA compared to  $AlCl_3$  group. Also, AG group showed highly significant increase in plasma level of GSH, SOD and CAT with highly significant decrease in plasma level of MDA compared to the control group.

This could be attributed to the excellent antioxidant properties of AG; these properties seem to be due to its ability to scavenge free radicals<sup>32</sup>. AG is also rich in antioxidants which reported to have strong reducing effect on lipid peroxidation<sup>17</sup>.

AG reported to have antioxidant effect which improve lipid metabolism in experimental animal studies<sup>33</sup>. Such results were previously provided by **Ahmed et al.**<sup>34</sup> who stated that AG may improve the hepatic expression of oxidative stress genes hence improve antioxidant status.

**Kaddam et al.**<sup>35</sup> founded that AG has a potent antioxidant effect on sickle cell anemia and other diseases characterized by oxidative stress. Also **Kamal et al.**<sup>36</sup> studied the effect of AG and founded that AG has a favorable immune modulator effect on rheumatoid arthritis.

Also **Gamal El-din et al.**<sup>37</sup> reported that AG has anti-inflammatory effect and used internally and externally for the treatment of inflammation.

As regarding fertility profile, the current study revealed that  $AlCl_3$  resulted in highly significant decrease in testosterone hormone level, sperm count, sperm motility, sperm viability with highly significant increase in total sperm abnormality.

**Pandey and Jain**<sup>38</sup> reported that aluminum may be responsible for decrease in sperm motility, viable sperms and causes morphological abnormalities.

Also **AL Dera and Abushouk**<sup>39</sup> and **Pandey and Jain**<sup>38</sup> postulated that aluminum impairs the male fertility and disturbs spermatogenesis by oxidative stress mechanism and decrease in the serum testosterone, follicle stimulating hormone and luteinizing hormone. **Guo et al.**<sup>9</sup> and **Yousef et al.**<sup>40</sup> founded that high levels of aluminum in spermatozoa and seminal plasma of humans resulted in decrease in sperm viability and motility.

As regarding the histopathological study, it caused degeneration in spermatogenic epithelium and loss of the releasing spermatozoa. Also pyknotic nuclei of the spermatogenic cell were seen; the interstitial spaces show eosinophilic fluid (edema) with infiltration of mononuclear cells and vacuolation.

**Hammoud and Shalaby**<sup>30</sup> stated that aluminum intoxication resulted in degeneration of spermatogoneal cells lining seminiferous tubules and incomplete spermatogenesis.

## V. Conclusion

From the results of the current study it can be concluded that Arabic gum is an effective protective agent against aluminum chloride-induced fertility impairment and oxidative stress due to its ability to decrease the oxidative stress and preserve the activity of antioxidant enzymes.

## References

- [1]. **Scheting M.R.C., Morsch V.M. and Bohrer D. (2002):** Aluminum: Interaction with nucleotides and nucleotidases and analytical aspects of determination; 104: 99-137.
- [2]. **Kim M.S. and Clesceri L.S. (2001):** Aluminum exposure: A study of an effect on cellular growth rate. *Sci. Total Environ*; 278(1-3), 127-135.
- [3]. **El-Demerdash F.M. (2004):** Antioxidant effect of vitamin E and selenium on lipid peroxidation, enzyme activities and biochemical parameters in rats exposed to aluminum. *J. Trace Elem. Med. Biol*; 18(1): 113-121.
- [4]. **Guo CH., Hus G.W., Chuang CH. and Chen P. (2009):** Aluminum accumulation induced testicular oxidative stress and altered selenium metabolism in mice. *Environ Toxicol Pharmacol*; 27: 176-181.
- [5]. **Bhattacharjee S., Zhao Y., Hill J.M., Culicchia F., Kruck T.P., Percy M.E., Pogue A.L., Walton J.R., Lukiw W.J. (2013):** Selective accumulation of aluminum in cerebral arteries in Alzheimer's disease (AD). *J Inorg Biochem.*; 126: 35-37.
- [6]. **Pandey G. and Jain G.C. (2017):** Aluminium chloride -induced testicular effects in rats. A histomorphometrical study. *Asian Journal of Applied Science and Technology*, 1(9): 46-52.
- [7]. **Ghorbel I., Chaabane M., Elwej A., Boudawara O., Abdelhedi S., Jamoussi K., Boudawara T. and Zeghal N. (2016):** Expression of metallothioneins I and II related to oxidative stress in the liver of aluminium-treated rats. *Arch. Physiol. Biochem.* 122:214-222.
- [8]. **Sharma S., Sharma R.K., Sharma R., Sharma A., Rai A.K., Gupta R.S. and Singh Y. (2003):** Synthesis and characterization of some new aluminium derivatives of Schiff bases containing N, O and S donor atoms and the antifertility activity of the derivative Al. *Chemistry Applied Bioinorganic Chemistry Applied*; 1: 215-225.

- [9]. **Guo CH., Lu Y. and Hsu G.W. (2005):** The influence of aluminium exposure on male reproduction and offspring in mice. *Environmental Toxicology Pharmacology*, 20(1):135-141.
- [10]. **Dong-Ping X.U., Zheng J., Zhou Z., Li Y. and Li H.B. (2017):** Ultrasound-assisted extraction of natural antioxidants from the flower of *Limonium sinuatum*. Optimization and comparison with conventional methods. *Food Chemistry*, 217: 552-559.
- [11]. **Ahmed A.A., Fedail J.S., Musa H.H., Musa T.H. and Sifaldin A.Z. (2016):** Gum Arabic supplementation improved antioxidant status and alters expression of oxidative stress gene in ovary of mice fed high fat diet. *Middle East Fertility Society Journal*, 21: 101-108.
- [12]. **Wyasu G. and Okereke N.Z.J. (2012):** Improving the film forming ability of Gum Arabic. *J. Nat. Prod. Plant Resour*; 2:314-317.
- [13]. **Patel S. and Goyal A. (2015):** Applications of natural polymer Gum Arabic: A Review. *International Journal of Food Properties*; 18(5):986-998.
- [14]. **Ayaz N.O., Ramadan Kh S., Farid H.E.A. and Alnahdi H.S. (2017):** Protective role and antioxidant activity of Arabic Gum against trichloroacetate-induced toxicity in liver of male rats. *Indian J. Anim. Res.*, 51:303-309.
- [15]. **Rehman K. U., Codipilly C. N. and Wapnir R. A. (2004):** Modulation of small intestinal nitric oxide synthase by Gum Arabic. *Exp Biol Med.*, 229: 895-901.
- [16]. **Pal R., Hooda M. S., Chain S.B. and Janardhan S. (2014):** Hepatoprotective Activity of *Acacia senegal* Pod against Carbon Tetrachloride-Induced Hepatotoxicity in Rats. *Int. J. Pharm. Sci. Rev. Res.*, 26: 165-168.
- [17]. **Ali B.H., Ziada A. and Blunden G. (2009):** Biological effects of Gum Arabic: a review of some recent research. *Food Chem. Toxicol.*, 47: 1-8.
- [18]. **Al-Majed A.A., Abd-Allah A.R., Al-Rikabi A.C., Al-Shabanah O.A., Mostafa A.M. (2003):** Effect of oral administration of Arabic gum on cisplatin-induced nephrotoxicity in rats. *J Biochem Mol Toxicol*; 17(3): 146-153.
- [19]. **Chiroma S. M., Moklas M. A. M., Taib C. N. M., Baharudin M. T. H., Amon Z. (2018):** D-galactose and aluminium chloride induced rat model with cognitive impairments. *Biomedicine & Pharmacotherapy*; 103, 1602- 1608.
- [20]. **Beutler E., Duron O., and Kelly B.M. (1963):** Improved method for the determination of blood glutathione. *J. Lab. Clin. Med*; 61:882-888.
- [21]. **Nishikimi M., Rao N.A. and Yagi K. (1972):** The occurrence of superoxide anion in the reaction of reduced phenazinemethosulfate and molecular oxygen. *Biochem. Biophys. Res. Commun*; 46: 849-854.
- [22]. **Onkawa H., Ohishi N. and Yagi K. (1979):** Assay for lipid peroxides in animal tissues by thiobarbituric acid reaction. *Anal. Biochem*; 95:351-358.
- [23]. **Sinha K (1972):** Colorimetric assay of catalase. *Anal Biochem*; 47:389-394.
- [24]. **Wilson J and Foster D (1992):** Williams text book of Endocrinology. 1st Ed, chapter 6: 923-926 Saunders co, Philadelphia Santener, S.
- [25]. **Bearden H. and Flaquary J. (1980):** Applied Animal Reproduction. Reston Publish-4th Ed Co, Jnc Reston, Virginia: 158-160.
- [26]. **Banchroft J.D., Stevens A. and Turner D.R. (1996):** Theory and Practice of Histological Techniques. Fourth (ed). Churchill Livingstone, New York, London, San Francisco, Tokyo, 125 pp.
- [27]. **Kinawy A. (2019):** Effects of drinking water containing aluminum and fluoride salts on the learning behavior and brain neurotransmitters of male rat offspring. *Egyptian Journal of Zoology*, 71: 1-12.
- [28]. **Klotz K., Weistenhöfer W., Neff F., Hartwig A., Thriel C.V., Drexler H. (2017):** The health effects of aluminum exposure. *DtschArzteblInt*; 114 (39):653-659.
- [29]. **Abdelazem H.M. (2019):** Effect of Moringa oleifera on antioxidant enzymes and oxidative stress induced by aluminium exposure in male albino rat testes. *International Journal of Cancer and Biomedical Research (IJCBR)*; 4(3): 34-41.
- [30]. **Hammoud G.M. and Shalaby R.A. (2019):** Experimental evaluation of protective action of resveratrol against aluminum-induced toxicity in male rats. *Int. J. Adv. Res. Biol. Sci.*; 6 (1):11-24.
- [31]. **Cheraghi E., Golkar A., Roshanaei K. and Alani B. (2017):** Aluminium-induced oxidative stress, apoptosis and alterations in testicular tissue and sperm quality in Wistar rats. Ameliorative effects of curcumin. *International Journal of Fertility and sterility*; 11(3): 166-175.
- [32]. **Ali B.H. (2004):** Does gum Arabic have an antioxidant action in rat kidney? *Ren Fail.*; 26(1):1-3.
- [33]. **Babiker R., Elmusharaf K., Keogh M.B., Saeed A.M. (2018):** Effect of Gum Arabic (*Acacia Senegal*) supplementation on visceral adiposity index (VAI) and blood pressure in patients with type 2 diabetes mellitus as indicators of cardiovascular disease (CVD): a randomized and placebo-controlled clinical trial. *Lipids Health Dis*; 17(1):56.
- [34]. **Ahmed A.A., Fedail J.S., Musa H.H., Kamboh A.A., Sifaldin A.Z., Musa T.H. (2015):** Gum Arabic extracts protect against hepatic oxidative stress in alloxan induced diabetes in rats. *Pathophysiology*; 22(4):189-194.
- [35]. **Kaddam L., Fadl-Elmula I., Eisawi O.A., Abdelrazig H.A., Salih M.A., Lang F., et al. (2017):** Gum Arabic as novel antioxidant agent in sickle cell anemia, phase II trial. *BMC Hematol*; 17:4 <https://doi.org/10.1186/s12878-017-0075-y>.
- [36]. **Kamal E., Kaddam L.A., Dahawi M., Osman M., Salih M.A., Alagib A., et al. (2018):** Gum arabic fibers decreased inflammatory markers and disease severity score among rheumatoid arthritis patients, phase II trial. *Int J Rheumatol*; 4197537.
- [37]. **Gamal El-din A.M., Mostafa A.M., Al-Shabanah O.A., Al Bekairi A.M., Nagi M.N. (2003):** Protective effect of Arabic gum against acetaminophen-induced hepatotoxicity in mice. *Pharmacol Res.*; 48(6):631-635.
- [38]. **Pandey G. and Jain G.C. (2013):** A review on toxic effects of aluminium exposure on male reproductive system and probable mechanisms of toxicity. *International Journal of Toxicology and Applied Pharmacology*, 3(3):48-57.
- [39]. **AL Dera H.S. and Abushouk A. (2015):** Protective effect of resveratrol against aluminium chloride (ALCL<sub>3</sub>) induced testicular damage in rats entails inhibition of intrinsic apoptotic pathway. *Sci. Adv. Mater.* 7:384-395.
- [40]. **Yousef M.I., Kamel K.I., El-Guendi M.I. and El-Demerdash F.M. (2007):** An in vitro study on reproductive toxicity of aluminium chloride on rabbit sperm. The protective role of some antioxidants. *Toxicology*; 239(3): 213-223.

Sahar M. Abo El Wafa, et. al. "Can Arabic gum improve the fertility impairment and ameliorate the oxidative stress induced by aluminum chloride in male rats?" *IOSR Journal of Environmental Science, Toxicology and Food Technology (IOSR-JESTFT)*, 14(8), (2020): pp 01-07.